

The functional bandage in the control of edema by the occupational therapist: case study**A bandagem funcional no controle do edema pelo terapeuta ocupacional: estudo de caso****El vendaje funcional en el control del edema por el terapeuta ocupacional: un estudio de caso****Camilla Rodrigues Guerra¹, Daniela Tonús¹****Received:** 10/03/2021 **Accepted:** 05/02/2022 **Published:** 29/06/2022

Objective: to verify the effectiveness of functional bandage as a complement to the treatment of occupational therapists in the control of edema. **Methods:** descriptive and exploratory case study carried out between September and October 2018, in a public hospital. Functional bandage was applied with evaluation of edema before and after application. **Results:** a female patient, 46 years old, with femoral shaft fracture participated in the study. In the first evaluation, a circumference of 65.5 cm was found in the swollen segment and, after the use of the bandage, there was a reduction of 4 cm. The second participant was male, 30 years old, had a fracture of the distal diaphysis of the tibia, initially presenting a circumference of 31 centimeters and, after using the bandage, there was a decrease of 2 centimeters. **Conclusion:** it was observed effectiveness in the use of the bandage in edema, with improvement in analgesia, independence and performance of occupations.

Descriptors: Athletic Tape; Angioedema; Occupational therapy.

Objetivo: verificar a efetividade da bandagem funcional como complemento ao tratamento de terapeutas ocupacionais no controle do edema. **Método:** estudo de caso descritivo e exploratório realizado entre setembro e outubro de 2018, em hospital público. Utilizou-se a aplicação da bandagem funcional com avaliação na medida do edema antes e após aplicação.

Resultados: participou do estudo uma paciente do gênero feminino, 46 anos, fratura da diáfise do fêmur. Na primeira avaliação constatou-se uma circunferência de 65,5 cm no segmento edemaciado e após o uso da bandagem houve uma redução de 4 cm. O segundo paciente participante foi de gênero masculino, 30 anos, fratura da diáfise distal da tíbia, apresentando inicialmente 31 centímetros de circunferência e após o uso da bandagem houve uma diminuição de 2 centímetros. **Conclusão:** observou-se eficácia na utilização da bandagem em edema, havendo melhora na analgesia, independência e realização das ocupações.

Descritores: Fita atlética; Angioedema; Terapia ocupacional.

Objetivo: comprobar la eficacia del vendaje funcional como complemento al tratamiento de los terapeutas ocupacionales en el control del edema. **Método:** estudio de caso descriptivo y exploratorio realizado entre septiembre y octubre de 2018, en un hospital público. Se utilizó la aplicación del vendaje funcional con la evaluación en la medición del edema antes y después de la aplicación.

Resultados: participó en el estudio una paciente de 46 años, con fractura de la diáfisis femoral. En la primera evaluación se encontró una circunferencia de 65,5 cm en el segmento edematoso y tras el uso del vendaje hubo una reducción de 4 cm. El segundo paciente era de sexo masculino, 30 años, con una fractura de la diáfisis de la tibia distal, con una circunferencia inicial de 31 centímetros, y tras el uso del vendaje hubo una reducción de 2 centímetros. **Conclusión:** se observó la eficacia del uso del vendaje en el edema, mejorando la analgesia, la independencia y la realización de las ocupaciones.

Descriptor: Cinta atlética; Angioedema; Terapia ocupacional.

Contact: Camilla Rodrigues Guerra - camilla_guerra@live.com

INTRODUCTION

Trauma-orthopedics is the union of two medical clinics that involve a multiplicity of pathologies, such as: fractures, tendon injuries, nerve injuries, dislocations, amputations, among others, affecting the musculoskeletal tissues of the human body. The most common symptoms related to these affections are pain and edema¹.

Pain is a public health problem, precisely due to the numerical range of medical cases whose origin is related to it². Edema is characterized by the excessive accumulation of fluid in the extracellular spaces. There are two general causes: the abnormal leakage of plasma fluid into the interstitial spaces through the capillaries and the inability of the lymphatic vessels to return fluid from the interstitium to the blood, which is known as lymphedema³.

Edema can occur acutely or in chronic conditions, as well as in different phases: mild, moderate or severe. The most common clinical manifestations are: increased perimeter, progressive volume of the affected limb, pain, loss of sensitivity, strength, mobility and different skin color. If not treated properly, it predisposes to systemic and fatal infection⁴.

Within the trauma-orthopedic clinic, traumas are also considered to cause edema and impairment of the locomotor system. A trauma is characterized by the transfer of energy from an external agent to the body, responsible for injuries, bruises and fractures¹.

The occupational therapist (OT) studies and works with everyday occupations and the impact on occupational performance and, consequently, on the quality of life of subjects, especially those with limitations or difficulties². To this end, the OT makes use of techniques and equipment that assist in rehabilitation and recovery, and one of the current approaches used in this context is the functional bandage.

The functional bandage was initially developed by Kenzo Kase, in 1973, based on chiropractic and kinesiology, recommending muscle movements and activities as essential to maintain and recover health⁵. It is presented as a thin, porous elastic tape made of 100% cotton material. It does not contain any type of medication and is water resistant and can remain on the skin for several days⁵.

The bandage is a resource that has also been used for the treatment of neuromuscular disorders, sports injuries and lymphatic drainage. It is able to stimulate proprioception; activate the endogenous analgesic system; correct common muscle and joint problems; in addition to inhibiting the congestion of body fluids. The main focus of the use of the bandage is to facilitate and promote the achievement of objectives such as: pain relief, realignment and functional reeducation of static and dynamic musculoskeletal structures and improvement of the circulation of body fluids⁶.

This resource is still little used within the scope of the OT's performance, and it is necessary to search for evidence of its effectiveness. Therefore, we sought to elucidate this new approach to treatment and performance, basing its importance in the face of the therapeutic needs of the subjects in care. Thus, the aim of this study was to verify the effectiveness of functional bandage as a complement to the treatment used by occupational therapists in the control of edema in patients with traumato-orthopedic impairments.

METHOD

This is a case study with a descriptive and exploratory character, seeking to evaluate the effectiveness of functional bandage in the treatment of edema. The descriptive method proposes to characterize a certain phenomenon, generally using standardized data collection techniques, proposing the recording and analysis of the object of study⁷.

The research took place at the University Hospital of Santa Maria (HUSM), in the surgical clinic unit, specialty of traumatology and orthopedics, during the month of September and October 2018, totaling 40 days.

Eligible patients were: between 18 and 50 years old; with acute localized edema (from 0 to 1 month after the injury) or sub-acute (between 2 and 3 months) resulting from a traumato-orthopedic involvement; visible, at or near the compromised function. Patients with generalized or chronic edema were excluded; with severe circulatory impairments such as: thrombosis; renal system failure; open wounds at or near the application of the functional bandage; sensitive skin, which could present allergic reactions; in addition to suspected or confirmed pregnancy.

A questionnaire was used to demonstrate the need for the resource in the face of daily occupations. To assess the edema, a body measuring tape was used, measured in centimeters, in order to verify the circumference of the swollen limb, as well as the contralateral side. This assessment method considers whether the segment showed a reduction in edema after the use of the functional bandage, being reassessed weekly and the data analyzed quantitatively after the end of the study⁸.

The site was photographed and marked with a pen so that the next evaluations could take place at the exact location, allowing repeating the measurement and verifying how much the edema was reabsorbed.

The bandage was cut using the Fan Tape cut, as it inhibits the congestion of body fluids⁶. It was applied on muscles close to powerful and actively functioning ganglia. The application of the tape consisted of a 3 cm neutral base, adhered close to lymph node groups, starting in a

proximal to distal direction with up to a maximum of 25% traction, covering the region to be treated. During the intervention, the structure remained positioned in elongation to promote convolutions following the path of the lymphatic capillaries⁶. For the application, the first step was to leave the skin clean and dry. For this, alcohol and paper towels were used. Before cutting the tape, a test was performed to see if the patients had allergic reactions to the material.

Information to know the clinical history of patients was collected from the multidisciplinary electronic medical record available at the institution. Also, a field diary and photographic records were used to systematize the experiences during the research, as well as to record the speeches of the study participants, in order to capture the experience with the use of the tape.

There was consent from the institution, the responsible physician and the patient, who signed a Free and Informed Consent Form (FICT). The study was approved by the Ethics and Research with Human Beings Committee, under the number CAAE 91474218.1.0000.5346.

RESULTS

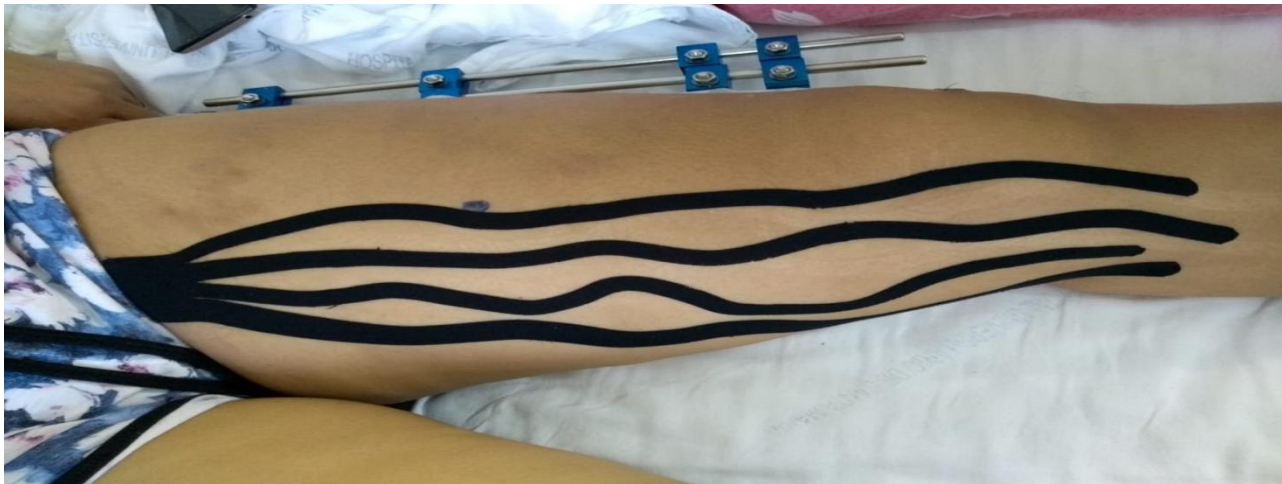Initially, 15 patients were evaluated, being considered for this study two hospitalized at the time of the research with edema in the Traumatology-Orthopedic clinic of the HUSM.

Patient 1

Female, 46 years old, works as a cleaner. She resided with her husband and four children. According to the electronic medical record, she had a history of systemic arterial hypertension and anxiety, undergoing pharmacological treatment. She suffered trauma from a motorcycle-car accident on September 9, 2018. She was riding the motorcycle and the collision was sideways. She was taken to the University Hospital of Santa Maria by SAMU, reported impact on the left lower limb-LLL and local pain. After imaging tests, the diagnosis of femoral shaft fracture was confirmed with surgical treatment.

She performed the surgical procedure on the same day with the placement of an external fixator. She underwent further surgery on October 4, 2018 to remove the device and two days later, she was discharged.

The first contact took place on the eighth day after the trauma and, consequently, in the postoperative period. The functional bandage was applied to the left lower limb, as shown in Figure 1.

Figure 1: Fan tape on the left lower limb, patient 1. Santa Maria, 2018.

The main occupational deprivation reported was that the edema was limiting knee flexion, influencing several occupational activities such as: walking; getting dressed; performance of personal hygiene; transfer and posture changes.

Seven days after the first application, the patient was on her fifteenth postoperative day. The edema was reassessed and the bandage was reapplied. On this day, she reported that she *did not feel any discomfort in using the tape, on the contrary, I only see benefits*. She mentioned that she noticed that *I urinated more during that week, could this fact be related to the use of the tape?* In addition, she also mentioned: *my pain has surprisingly decreased. I reduced the use of pain medication, I even stayed five consecutive days without taking any painkillers*.

It is observed in Table 1 that in the first application, the swollen segment was 65.5 cm in circumference and seven days later, it was 61.5 cm, that is, it had a reduction of four centimeters. However, in the other revaluations, the circumference of the segment did not decrease.

Table 1. Patient 1 second evaluation of edema. Santa Maria, 2018.

Application	Place	Segment Measurement	Contralateral Measurement
8 th day of post-op (PO)	Mid thigh	65.5 cm	62 cm
15 th day of PO	Mid thigh	61.5 cm	59 cm
22 th day of PO	Mid thigh	62 cm	58.5 cm
24 th day of PO	Mid thigh	61cm	58.5 cm

Patient 2

Male, 30 years old, single, works as a hairdresser. According to the previously healthy electronic medical record, he was taken to the University Hospital on August 30, 2018 by SAMU after being hit by a car. The patient reported an impact on the LLL with pain. After imaging tests,

a fracture of the distal diaphysis of the left tibia was found. On the same day, surgery was performed, using an external fixator as the treatment procedure. On September 22, he underwent surgery to remove the fixator. Three days later, he underwent surgical treatment for a fracture of the tibial plateau and was then discharged.

He had edema in the left lower limb, in which the main occupational deprivation in daily activities reported was the desire to walk and move around alone.

He was attended by the Occupational Therapy internship, twice a week, for which retrograde massage was performed as an intervention to treat the edema. During an interview, he mentioned that *massage helped in my treatment. Only after a massage I can move my toes*. In turn, the massage activity was suspended after using the bandage.

There were only two applications of the functional bandage in view of discharge and for personal reasons not being able to attend the meetings to continue the treatment of the edema. The tape was applied only to the dorsal region of the foot, due to having the external fixator and bandages, as can be seen in Figure 2. However, he reported that *the pain I felt up to the knee region decreased a lot*.



Figure 2. Fan tape on left foot. Santa Maria, 2018.

It is observed in Table 2 that the segment that was 31 centimeters in circumference decreased by two centimeters when it was reassessed, seven days after the application of the functional bandage. On this day, he reported: *I noticed improvement. When I received the retrograde massage, I felt comfortable and was able to move my toes only for a few hours afterwards, but using the bandage, I move my fingers at all times, in addition to reducing my pain*.

Table 2. Patient according to edema assessment. Santa Maria, 2018.

Application	Anatomical Point	Segment Measurement	Contralateral Measurement
10 th day of PO	Malleolus	31cm	25.5cm
17 th day of PO	Malleolus	29cm	26.5cm

DISCUSSION

Edema is seen when the interstitial fluid is about 30% above normal. It is expected, usually after surgery or trauma, however care must be taken to ensure that it does not become excessive or continuous. The central problem in the case of edema is found in the subcutaneous tissue layer, which accumulates fluid in the extravascular space and increases interstitial pressure, inhibiting the function of lymphatic and blood vessels, causing an increase in edema⁹.

There are alternatives that prevent and help in the treatment of this condition, such as: elevation of the affected limb; correct limb positioning; active mobilization; compressive bandaging; contrast bath; cryotherapy and retrograde massage⁹.

Currently, functional bandage is being used as a new treatment approach to control and reduce edema¹⁰. In addition to musculoskeletal knowledge, it is necessary to apply specific and appropriate technique.

The physiological effects of the bandage are divided into five types: analgesic; joint support; proprioception; blood and lymphatic circulation and neuroreflex¹¹. For lymphatic and circulatory correction in the control of edema, the bandage used with adequate tension directs the lymphatic and blood fluids to a place that does not have circulatory compromise⁵.

The bandage has the potential to help increase the interstitial space by lifting the skin, which allows the muscle fascia to regain its mobility and function. The action of mobilization of the epidermis in the dermis generates a space that quickly reduces pressure and restores the function of expulsion of excess liquids and macromolecules from the lymphatic system⁶⁻¹².

From the stretching and elasticity of the tissue, the skin rises forming superficial folds. These folds are produced directly through the application of the bandage, increasing the subcutaneous space, releasing pressure on the afferent and efferent receptors located there. Therefore, it provides lymphatic and blood circulation, reducing symptoms and the accumulation of inflammatory mediators that sensitize mechanoreceptors and nociceptors¹².

The lymphatic system plays a crucial role in the balance of body fluid, macromolecular, lipid absorption, immune function, among others. Diuresis results from several processes that are involved in the formation of urine. In addition to eliminating nitrogenous excreta and any low molecular weight water-soluble substance, the kidneys, with the endocrine and cardiovascular systems, maintain the hydroelectrolytic balance¹³. To eliminate the edema, the collecting vessels receive the lymph and take it to the lymph nodes. The lymph then travels towards the kidneys where toxins are filtered and eliminated through urine and feces¹⁰⁻¹².

This mechanism explains the action of the bandage and how it influences physiologically¹². In this way, it provides a basis for its possible effectiveness. Therefore, it can

be considered that, in this specific case, the fact that Participant 1 of the study urinated more frequently was an expected response from the body, which is eliminating the excess accumulated liquid.

In addition, a decrease in pain symptoms was observed with the use of the tape, that is, it reverberated in the subject's performance components, providing greater comfort to perform their activities even in a hospital environment. Pain is usually associated with the deterioration of health and, when it occurs, it affects the development of daily activities, directly interfering with activities of daily living, sleep quality, social interactions and physical abilities. The thin strips of the Fan Tape cut reduce excess heat and chemical substances in the tissue, and thus, the discomfort, pain and inflammation caused by edema and hematomas^{6,10-11}. Thus, patients, when using the bandage, benefited from this resource, but its analgesic effect still does not present robust scientific results.

A systematic review on the application of this technique as a pain reduction strategy indicated its short-term use. This study highlighted that the application of the bandage as an alternative or complementary treatment shows its immediate and short-lasting effect only after application, suggesting the association of this technique with other resources¹⁴.

In both patients, there was effectiveness in the use of the functional bandage in relation to edema, with improvement also in terms of analgesia and consequently for independence in performing the reported occupations, at first as compromised. Participant 1 had a reduction of four centimeters of edema in the affected segment and Participant 2 had a reduction of two centimeters in circumference in the segment, both in the first seven days. Thus, it is understood that Occupational Therapy can use this resource as an adjunct in the treatment of people with edema, in view of its benefits in these situations and its connection with well-being and independence in occupations.

There was a lack of research that relates the functional bandage with the control of edema and pain, with a predominance of studies that verify the action of this technique in the physical performance of athletes.

A study on the bandage in patellofemoral pain syndrome identified positive results in mobility and pain intensity of individuals who used the tape, as well as immediate pain reduction¹⁵. In this case, the application of the elastic tape for the treatment of patellofemoral syndrome, took place from the application of the tape, and if the pain decreased, it should remain the same. Otherwise, if the tape had no influence on the pain, it would be removed. It is observed, therefore, that the functional elastic bandage lacks tests of greater amplitude.

CONCLUSION

The effectiveness of the functional bandage was verified as a complementary resource in the treatment of edema, due to the short-term positive result, with no evidence that the effects are prolonged. In addition, the improvement of the general condition of patients, such as pain relief and favorable conditions for performing occupations, can be considered a relevant issue in the work of the occupational therapist.

Although the case study makes it possible to examine the effects of the intervention carefully and in considerable detail, its design limits the generalizability of the results to a population. Also, study time and sample size can be a limiting factor. Likewise, there is a lack of scientific publications on the subject. Therefore, the need for more studies and related publications is reinforced, since its effectiveness as a complementary intervention to the treatment of edema has been identified.

Despite the limitations, this study highlighted the importance of bringing and testing resources that are relevant to the practice of occupational therapists, aiming to guide behaviors and propose a better treatment plan.

REFERENCES

1. Oliveira WC, Vicentin EL, Nascimento RM, Oliveira AG, Bernardelli AMM. Traumas, contusões e fraturas. *Vitrine Prod Acad.* 2015; 3(2):48-52. Available from: <https://docplayer.com.br/50098413-Artigo-cientifico-traumas-contusoes-e-fraturas.html>
2. Fuchs M, Cassapian MR. A Terapia Ocupacional e a dor crônica em pacientes de Ortopedia e Reumatologia: revisão bibliográfica. *Cad Ter Ocup UFSCar.* [Internet]. 2012 [cited in 10 Nov 2018]; 20(1):107-19. DOI: <http://dx.doi.org/10.4322/cto.2012.012>
3. Pivetta HMF, Petter GN, Santos LF, Martins TNO. Efeitos do Kinesio Taping sobre o edema linfático. *Fisioter Bras* [internet]. 2017 [cited in Apr 2022]; 18(3):382-90. DOI: <https://doi.org/10.33233/fb.v18i3.1067>
4. Jiménez-Anula J, Nieto-Gálvez V. Eficacia del Kinesiotaping frente al vendaje multicapa en el tratamiento del linfedema postmastectomia [Internet]. [trabalho de conclusão de curso]. Jaén, Espanha: Universidad de Jaén; 2014 [cited in 14 Aug 2020]. Available from: https://tauja.ujaen.es/jspui/bitstream/10953.1/1524/1/TFG%20NIETO_G%c3%81LVEZ_VE R%c3%93NICA.pdf
5. Kase K, Lemos TV, Dias EM, organizadores. *Kinesio Taping. Introdução ao método e aplicações musculares.* 2ed. São Paulo: Andreoli; 2013. 144p.
6. Antello CG. *Taping Terapêutico Funcional. Módulo Reabilitação de MMSS* [apostila]. Santa Maria (RS), 2017. 33p.
7. Gil AC. *Como elaborar projetos de pesquisa.* 7ed. São Paulo: Atlas; 2022. 208p.
8. Mello MAF, Mancini MC. Métodos e técnicas de avaliação nas áreas de desempenho ocupacional. In: Cavalcanti A, Galvão C., organizadoras. *Terapia ocupacional fundamentação & prática.* 1ed. Rio de Janeiro: Guanabara Koogan; 2007. p.49-73.
9. Afonso PGCM, Figueiredo IM. Edema traumático na mão. In: Freitas PP, organizadora. *Reabilitação da mão.* 1ed. São Paulo: Atheneu; 2006. p.69-79.

10. Vidal JG, Camargo FJS. Eficacia del vendaje neuromuscular en el edema postquirúrgico o postraumático [Internet]. [trabalho de conclusão de curso]. Coruña, Espanha: Universidade da Coruña; 2017 [cited in 01 Apr 2022]. 62p. Available from: https://ruc.udc.es/dspace/bitstream/handle/2183/20571/Garc%C3%ADaVidal_Javier_TFG_2017.pdf?sequence=2
11. Aragón FJA, Prado MLU. Vendaje neuromuscular y cicatrización de heridas, un camino por explorar. Enfermería Dermatológica [Internet]. 2017 [cited in 15 Aug 2020]; 11(30):7-11. Available from: <https://dialnet.unirioja.es/descarga/articulo/6091056.pdf>
12. Chicaíza XMV. Vendaje neuromuscular: efectos neurofisiológicos y el papel de las fascias. Rev Cienc Salud (Bogotá) [Internet]. 2014 [cited in 28 Nov 2018]; 12(2):253-69. Available from: <https://revistas.urosario.edu.co/index.php/revsalud/article/view/3082/2462>
13. Camargo EAM, Marcorin DM, Silva BD, Helleno LG, Marcondes MCCG, Kassisse DMG, et al. Composição urinária de homens e mulheres após drenagem linfática manual. Fisioter Bras. [Internet]. 2015 [cited in 19 Aug 2020]; 16(2):148-54. Available from: <https://portalatlanticaeditora.com.br/index.php/fisioterapiabrasil/article/view/287/490>
14. Artioli DP, Bertolini GRF. Kinesio taping: aplicação e seus resultados sobre a dor: revisão sistemática. Fisioter Pesq. [Internet]. 2014 jan/mar [cited in 21 Nov 2018]; 21(1):94-9. Available from: <https://www.scielo.br/j/fp/a/LTrVSBPGCpYv7Z9ntV4VpwB/?format=pdf&lang=pt>
15. Oliveira LMR, Guimarães LAM. Bandagem funcional na síndrome da dor patelofemoral: uma revisão sistemática [Internet]. [trabalho de conclusão de curso]. Pindamonhangaba (SP): Faculdade de Pindamonhangaba; 2013 [cited in 01 Apr 2021] . 44p. Available from: <https://docplayer.com.br/44229332-Bandagem-funcional-na-sindrome-da-dor-patelofemoral-uma-revisao-sistematica.html>

Associated Publisher: Víctor Augusto Cavaleiro Corrêa

Conflict of Interest: the authors declare that there is no conflict of interest

CONTRIBUTION

Camilla Rodrigues Guerra was responsible for the design, data collection and analysis and writing. **Daniela Tonus** contributed to the revision.

How to cite this article (Vancouver)


Guerra CR, Tonús D. The functional bandage in the control of edema by the occupational therapist: case study. *Rev. Fam., Ciclos Vida Saúde Contexto Soc.* [Internet]. 2022 [cited in *insert day, month and year of access*]; 10(2):230-40. Available from: *inset access link*. DOI: *insert DOI link*.

How to cite this article (ABNT)

GUERRA, C. R.; TONÚS, D. The functional bandage in the control of edema by the occupational therapist: case study. **Rev. Fam., Ciclos Vida Saúde Contexto Soc.**, Uberaba, MG, v. 10, n. 2, p. 230-240, 2022. DOI: *insert DOI link*. Available from: *insert access link*. Access in: *insert day, month and year of access*.

How to cite this article (APA)

Guerra, C.R., & Tonús, D. (2022). The functional bandage in the control of edema by the occupational therapist: case study. *Rev. Fam., Ciclos Vida Saúde Contexto Soc.*, 10(2), 230-240. Retrieved in *insert day, month and year of access* from *insert access link*. DOI: *insert DOI link*.



This is an open access article distributed under the terms of the Creative Commons License